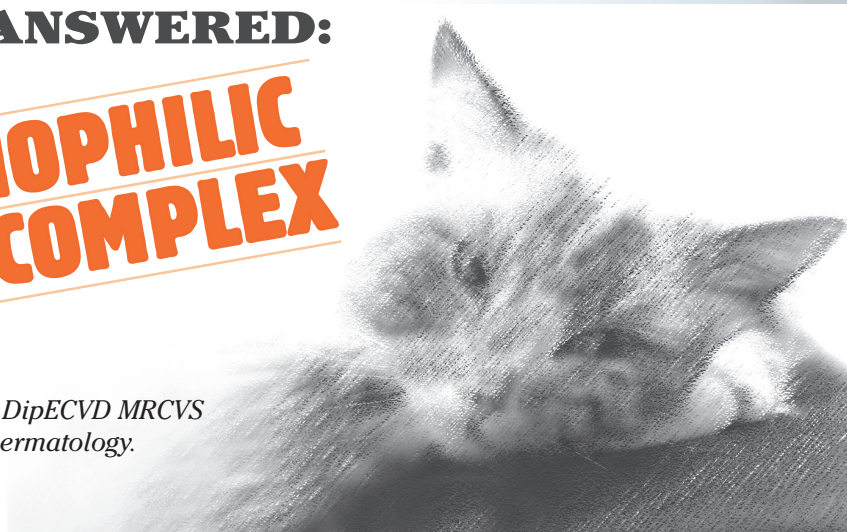




YOUR QUESTIONS ANSWERED:

FELINE EOSINOPHILIC GRANULOMA COMPLEX

*Natalie Barnard BVetMed CertVD DipECVD MRCVS
European Specialist in Veterinary Dermatology.*



WHAT IS FELINE EOSINOPHILIC GRANULOMA COMPLEX (EGC)?

This is a term used to describe a skin problem in cats that involves several different syndromes namely the indolent ulcer (rodent ulcer, eosinophilic ulcer), eosinophilic plaque and eosinophilic granuloma (linear granuloma). This term describes a cutaneous reaction pattern of the skin, which can arise from multiple different causes and should always highlight the need for a thorough investigation and logical diagnostic approach. An allergy investigation is often indicated.

WHAT ARE THE FEATURES OF AN INDOLENT ULCER?

- Usually associated with an underlying hypersensitivity.
- Common in cats.
- The lesion begins as a small crater-like ulcer with raised margin.
- Lesion distribution: commonly affects the upper lip, also reported in the oral cavity.
- Can be unilateral or bilateral.
- The lesion may enlarge progressively and become disfiguring.
- Not painful or pruritic.
- Regional lymphadenopathy: may be present.

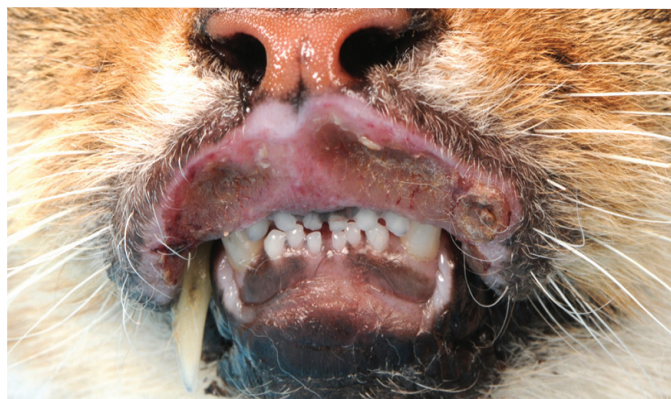
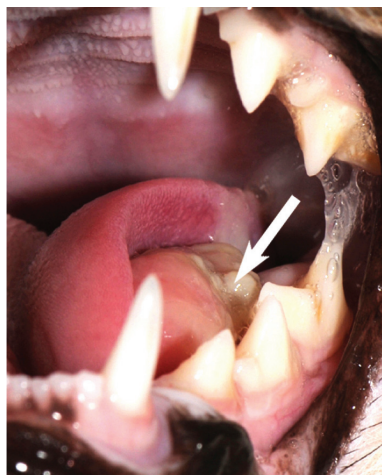

Fig.1: Indolent ulcer.

WHAT ARE THE FEATURES OF AN EOSINOPHILIC GRANULOMA?



- Usually associated with an underlying hypersensitivity.
- Common in cats.
- Lesions usually occur singly.
- Can be variable in appearance: they may be raised, firm, linear plaques or papular to nodular, oedematous or firm swellings. The lesions may be erythematous, ulcerated, alopecic, eroded.
- Usually not painful or pruritic.
- Lesion distribution: most common on the caudal aspect of the thigh (linear granuloma) and chin or lip (swelling). Oral cavity.
- Regional lymphadenopathy may be present.
- Lesions in the oral cavity are characterised by papules, nodules, or well circumscribed plaques – usually on the tongue or palate.
- Cats with oral lesions may be dysphagic.

Fig.2: Eosinophilic granuloma.



WHAT ARE THE FEATURES OF AN EOSINOPHILIC PLAQUE?

- Usually associated with an underlying hypersensitivity.
- Common in cats – highest incidence in young adult – middle aged cats.
- Single to multiple erythematous, well circumscribed, raised, eroded or ulcerated plaques.
- INTENSELY PRURITIC.
- Lesion distribution: anywhere on the body, commonly ventral abdomen and medial thighs.
- Regional lymphadenopathy: may be present.

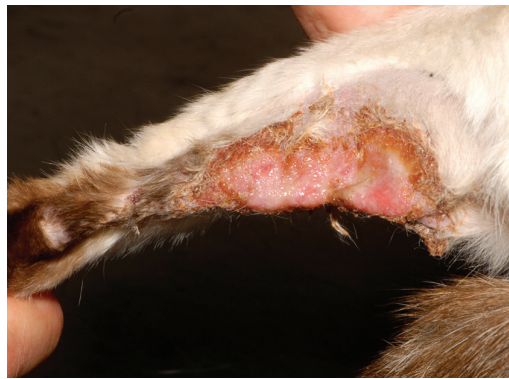

Fig. 3: Eosinophilic plaque.

WHAT ARE THE MAIN DIFFERENTIAL DIAGNOSES FOR EGC?

- Infections – bacterial, viral, fungal.
- Trauma.
- Neoplasia – squamous cell carcinoma, mast cell tumour, cutaneous lymphoma.

HOW DO WE DIAGNOSE EGC?

Diagnosis is usually based on history, clinical findings and ruling out other differentials. In some cases histopathology may be required if there is an unusual presentation, or if it does not respond to treatment. An impression smear from a moist lesion may reveal large numbers of eosinophils, but neutrophils and bacteria may predominate if the lesion is secondarily infected. A skin biopsy is also useful to characterise the lesion and will help rule out some of the differentials. The three types of lesion have characteristic histological appearances. Cats with an eosinophilic granuloma or eosinophilic plaque may have a peripheral eosinophilia.

Rarely dermatophytosis can present similarly in appearance to a lesion of the eosinophilic granuloma complex, so a fungal culture should be performed to exclude this differential.

Once a lesion of the eosinophilic granuloma complex has been identified then investigation to find the underlying cause should be undertaken. This will usually include a full allergy investigation to rule in/rule out flea allergy, cutaneous adverse food reaction and atopic dermatitis.

MANAGEMENT OF UNDERLYING CAUSES AND TREATMENT OF THE FELINE EOSINOPHILIC GRANULOMA COMPLEX LESIONS

THE MOST IMPORTANT THING IS TO ATTEMPT TO IDENTIFY AN UNDERLYING CAUSE AND MANAGE IT. This is not possible in all cases.

1. Management of underlying causes.

Managing Flea Allergy:

- Treat the affected animal and in contacts.
- Treat the environment.
- If the cat is extremely pruritic then systemic glucocorticoids may be appropriate.

Managing cutaneous adverse food reaction:

- This can be controlled by finding an appropriate diet to maintain the cat on, which may have been determined during the dietary trial period.

Managing atopic dermatitis:

- A combination of steroids, anti-histamines, fatty acid supplements and allergen specific immunotherapy may need to be used. Treatment will be tailored to the individual patient, with the aim being to find the least amount of medication that controls the clinical signs.

2. Treating the lesions of eosinophilic granuloma complex.

Treat secondary infection:

- Often several weeks of antibiotic treatment may be required if the lesion is secondarily infected. This can be determined by performing some cytology and examining it in house. External culture and sensitivity should be considered if rods are seen. Treat with an appropriate antibiotic dependant on what is seen on cytology, for a minimum of three weeks, or until a week after a clear cytological assessment for bacteria. Examples of commonly used antibiotics include cefalexin (at 15-20mg/kg BID) or clindamycin (at 11mg/kg SID). Some lesions are reported to resolve with antibiotic treatment alone.

Inducing remission of the lesion:

- This generally requires treatment with systemic glucocorticoids. An improvement is usually seen in 2-4 weeks of treatment and then treatment should be gradually tapered to the lowest possible alternate day dose and if possible discontinued if you can manage the underlying cause successfully.
- Suggested doses of glucocorticoids:
 - Prednisolone 1-2 mg/kg once daily until remission is achieved (2-8 weeks) then taper to lowest possible alternate day dose.
 - Methylprednisolone 0.8-1.6mg/kg once daily until remission is achieved then taper to lowest possible alternate day dose.
 - Methylprednisolone acetate – in the author's opinion this should only be used in cases that cannot be medicated orally at a dose of 4mg/kg SC or IM every 2-3 weeks. Once the lesions are in remission this should only be used as needed.
- Some lesions are refractory to glucocorticoids treatment and in these cases alternate therapies listed below may be useful.
 - Doxycycline 5-10 mg/kg every 12 hours.
 - Ciclosporin 7mg/kg once daily
- Anti-histamines (Cetirizine 5mg once daily) may be useful as a steroid sparing agent. In humans this is reported to inhibit exocytosis of eosinophils. Adverse effects are rarely reported, but mainly include excitation after administration and sedation.

Prognosis.

This is usually good if the underlying cause can be successfully managed, but cats that have recurring lesions where an underlying cause cannot be determined may require long term treatment with glucocorticoids to keep their lesions in remission. In these cases always try to find the least amount of medication which controls their clinical signs to minimise the risk of unacceptable adverse effects.

Further reading

1. Medleau, Hnilica. Small Animal Dermatology: A Colour Atlas and Therapeutic Guide, Second Edition, Saunders, 2006.
2. Scott DW, Miller WH Jr, Griffin CE. Muller & Kirk's Small Animal Dermatology VI. Philadelphia: WB Saunders, 2001.