

Hip Dysplasia Advice Sheet

What is Hip dysplasia?

Hip dysplasia is a complex condition in dogs and cats in which the hip develops abnormally as the young animal grows, resulting in abnormal articulation of the “ball and socket” hip joint between the femur (thigh bone) and pelvis. In a young animal with developing hip dysplasia, increased laxity of the structures supporting the hip joint result in the joint becoming unstable. Joint instability results in further abnormal development of the hip joint, with the femoral head (“ball” at the top of the femur) becoming flattened, and the acetabulum (“socket” of the pelvis) becoming shallow so that the femoral head is not properly located within the socket. Over time, the cartilage covering the femoral head and acetabulum becomes damaged, and osteoarthritis develops.

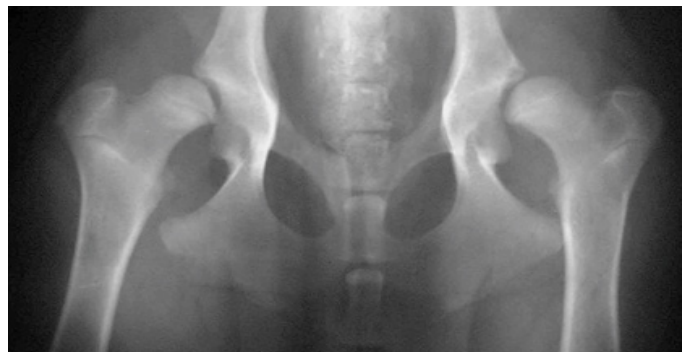What are the Clinical Signs of Hip Dysplasia?

Hip dysplasia affects all breeds but more commonly affects large breed dogs. In a young dog, signs may be seen at 5-12 months old. Severe hip laxity results in hip pain, difficulties rising, climbing or jumping, often associated with a “bunny hopping” or “swaying” hind limb gait. Signs may improve or resolve as the young animal matures. In adult animals, presentation is more variable both in the onset and the severity of clinical signs. Signs such as stiffness after rest or strenuous exercise, hip pain, reduced hip flexibility, hind limb lameness and reduced exercise tolerance relate to the progressive osteoarthritis that develops secondary to hip dysplasia. Signs may wax and wane in severity.

How is hip dysplasia diagnosed?

Orthopaedic examination may reveal lameness, hip pain and muscle loss over the

pelvis and hind limbs. Excessive hip laxity or a reduced range of hip motion may be present in young and adult animals respectively. X-rays of the hips are used to demonstrate the degree to which the hip formation is abnormal, and the presence and severity of secondary osteoarthritis. The severity of signs of hip dysplasia on x-rays does not always correlate to the severity of clinical signs.



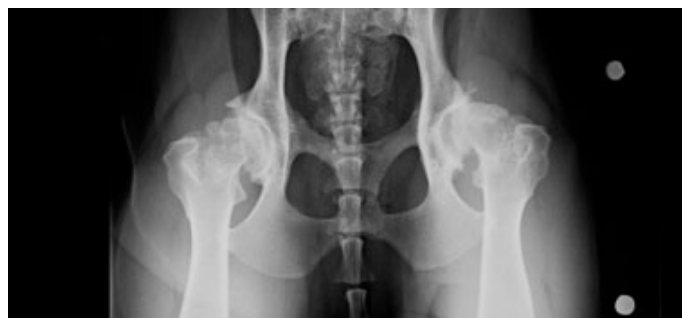An x-ray showing bilateral hip dysplasia in a young dog

How is Hip Dysplasia Treated?

The treatment options for hip dysplasia depend on several factors including the age of your dog at presentation and the severity of the dysplasia.

Conservative / non surgical treatment

Non-surgical treatment of hip dysplasia is targeted at limiting impact on the unstable painful joint in the young dog and managing the associated osteoarthritis in the older dog. Please see owner information regarding osteoarthritis for details.



An x-ray showing bilateral hip osteoarthritis

Hip Dysplasia Advice Sheet

Surgical treatment

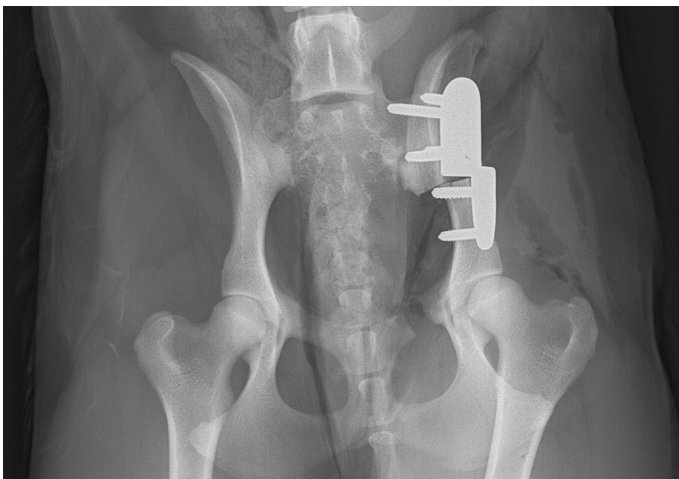
Juvenile pubic symphysiodesis (JPS)

Very young dogs (less than 16 weeks) with excessive hip laxity but without signs of osteoarthritis, may be candidates for Juvenile Pubic Symphysiodesis. This is a relatively simple procedure that aims to fuse a growth plate underneath the pelvis with the result that the rest of the pelvis grows more and the acetabulum or socket grows over the unstable ball of the femur.

Pelvic Osteotomy

Young dogs with hip dysplasia (typically under 10 months of age), with signs of excessive hip laxity but without signs of osteoarthritis, may be candidates for pelvic osteotomy. The procedure involves making two to three cuts in the pelvis and aims to rotate the acetabulum (hip "socket") to allow greater coverage of femoral head, reducing the instability of the hip joint.

Careful case selection is critical for this procedure. Despite decreasing the instability of the hip joint, subsequent osteoarthritis may still develop.



Post operative x-ray after DPO (double pelvic osteotomy) on a young dog

Salvage Surgery

Salvage surgeries are "last resort" procedures for treatment of conditions that result in long-term joint pain which is unlikely to or has not responded to conservative / non-surgical treatment, such as pain relief and exercise modification.

Femoral Head and Neck Excision

Femoral head and neck excision is a procedure that be used to address conditions that cause a painful hip, such as hip dysplasia, in both immature and adult animals, fractures of the femoral head, neck or growth plate, hip dislocation, or failed Total Hip Replacement. It can also be used to treat avascular necrosis of the femoral head, a condition where the blood supply to the femoral head is disrupted resulting in bone degeneration. The procedure involves removing the femoral head and neck (the "ball" of the hip joint at the top of the thigh bone). Over time, scar tissue forms a "false joint" between the pelvis and the femur (thigh bone) and the acetabulum and top of the femur remodel. Please see our separate information sheet regarding Femoral Head and Neck Excision.

Total Hip Replacement

The aim of total hip replacement is to allow dogs and cats with severely compromised mobility and hip pain, to return to exercising normally. Otherwise healthy, skeletally mature dogs and cats with severe hip dysplasia, severe hip osteoarthritis or complicated hip fractures or dislocations, are potential candidates for total hip replacement. Please see our separate information regarding total hip replacement.

Contact Us

T: 0117 394 0513 / 0514

E: sah@langfordvets.co.uk

langfordvets.co.uk

Langford Vets

University of
BRISTOL